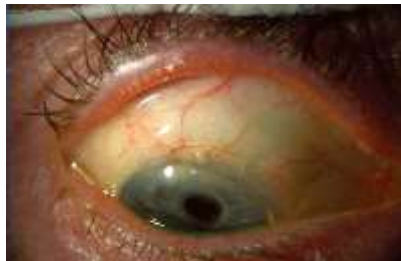

Better outcomes of Trabeculectomy

Ahmed Elkarmouty
Moorfields Eye Hospital

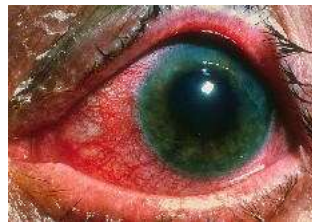- A successful trabeculectomy is a stable surgical fistula.
- The one thing required to keep a fistula patent (open) is **flow**.
- The principal and most challenging complication is scarring.



- The best outcomes of the trabeculectomy starts pre-operatively.
- This involves careful case selection before surgery, optimisation of the operating environment.
- In addition, patients should have been counselled prior to surgery so their expectations match their post-operative experience.

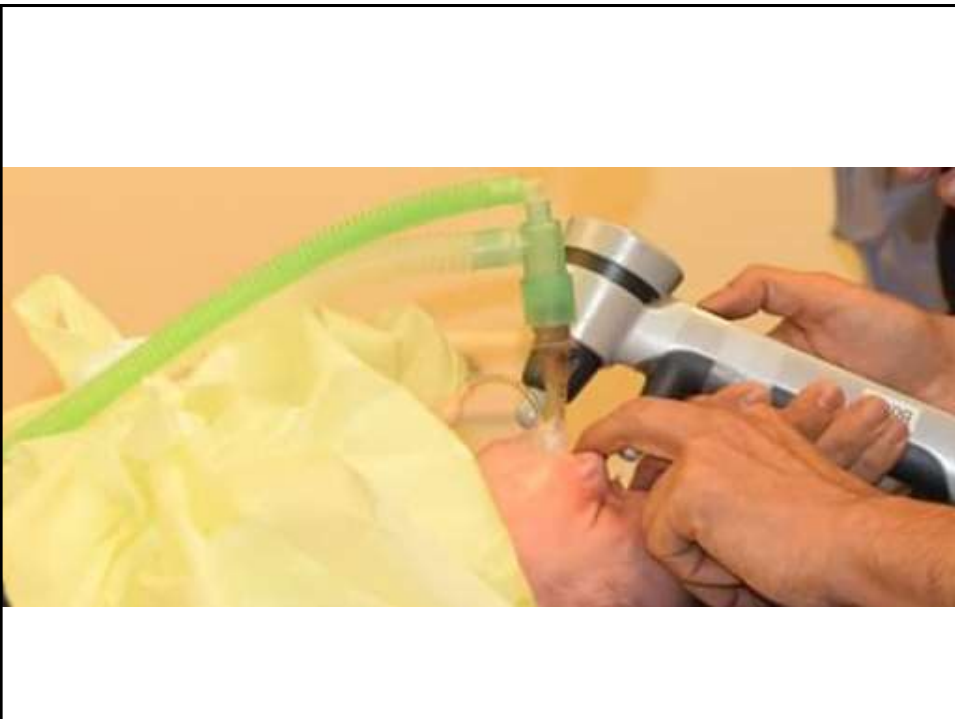
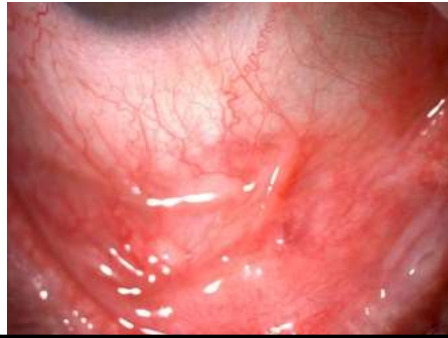
Case selection

- Higher failure rate, post conjunctival surgery, NVG, ICE syndrome, Aniridia, Aphakia, FHC, long use of drops with red eyes, complicated cataract surgery, failed Traby in the other eye.
- Avoid phaco/ traby surgery.
- Higher risk of hypotony, VKH, Behcet's, JIA, Sarcoidosis.

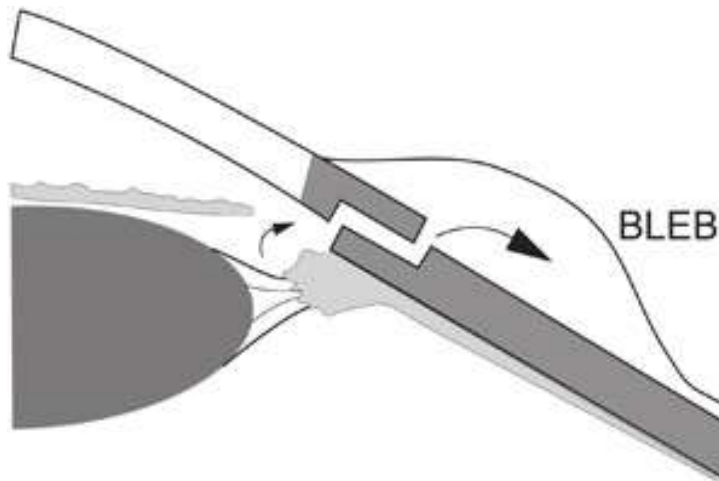
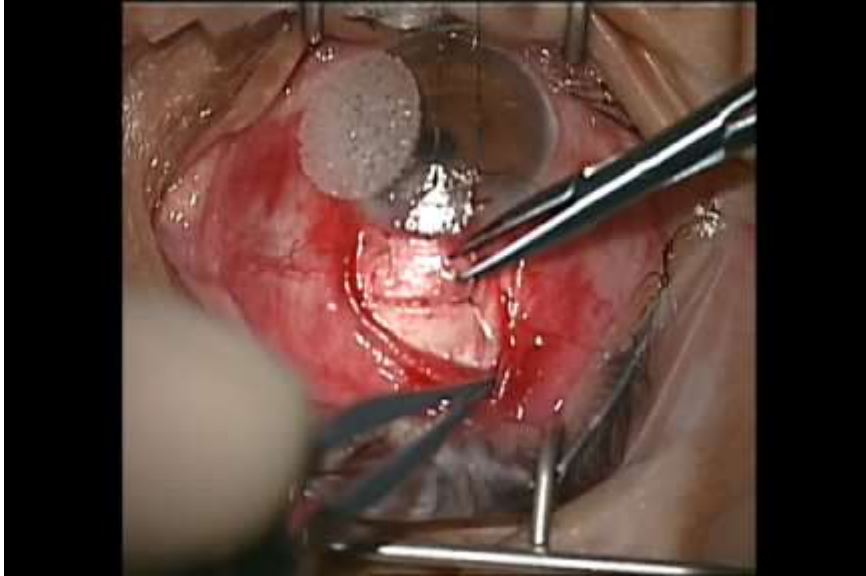


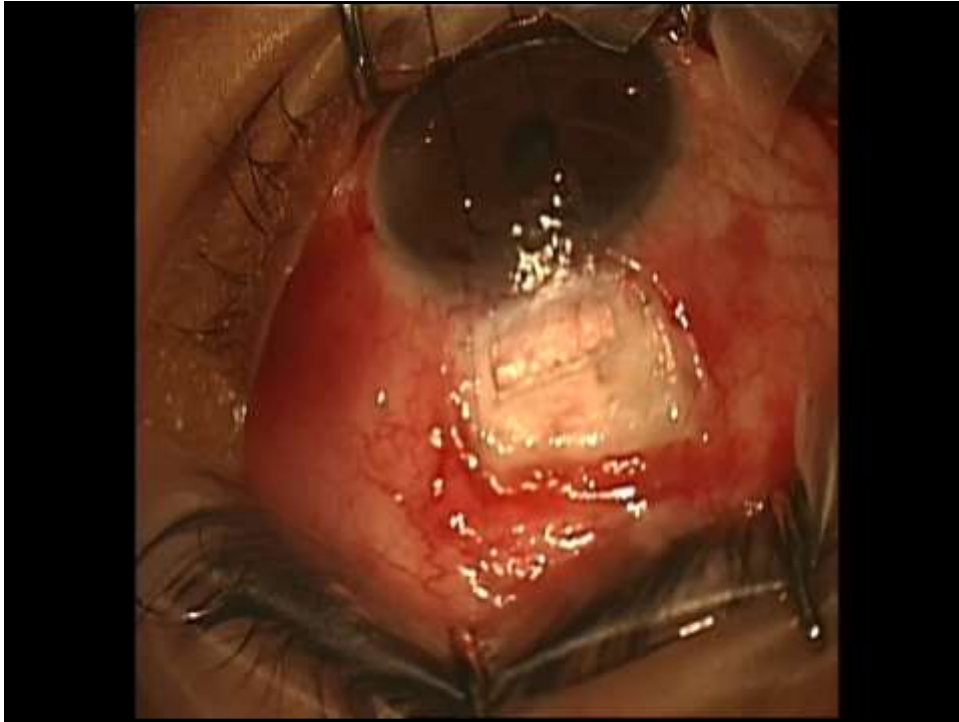
Case selection

- Higher risk of scarring : OCP, chemical burn.
- Higher risk of Complication: High myopia/ nanophthalmos, Sturge –weber.



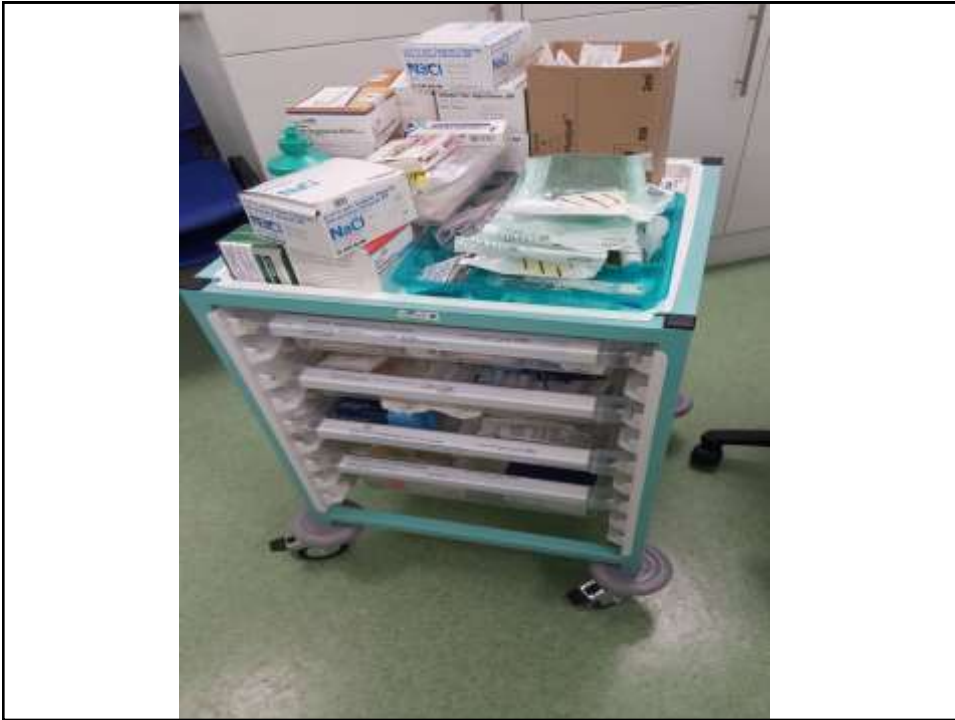Surgical technique





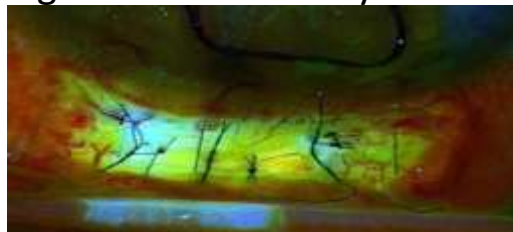Surgical technique

- One final point to recognise is that poor surgical technique can result in blebs that require permanent massage.
- If the arms of the trabeculectomy flap do not reach to the site of the sclerostomy, then this can have the effect of creating a valve only opened with pressure posteriorly.
- In this instance, re-exploration and revision is the only option to achieve a satisfactory long-term result.



Post- operative care

- The principal and most challenging complication is scarring. (+fear)
- Management of this risk factor can improve your success rates in trabeculectomy surgery by 10% or more if you identify the patients most at risk and manage them intensively.

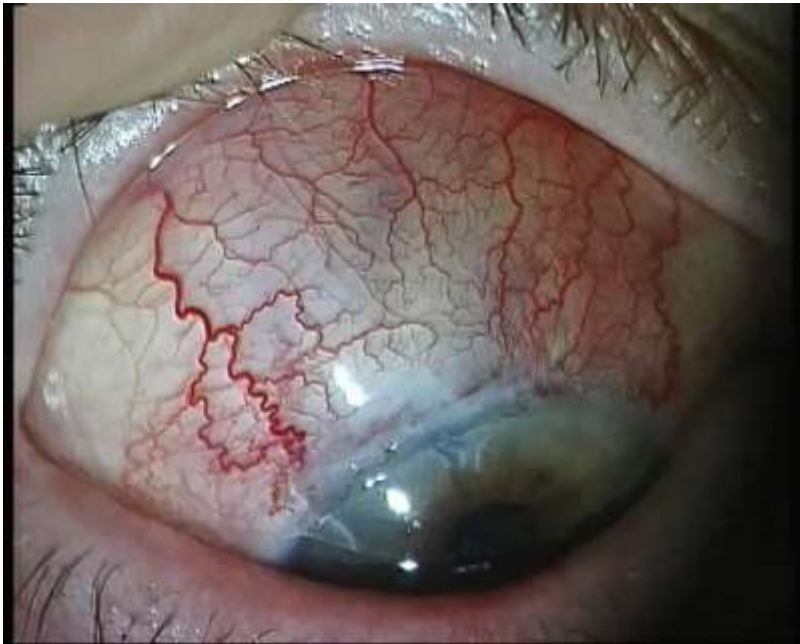

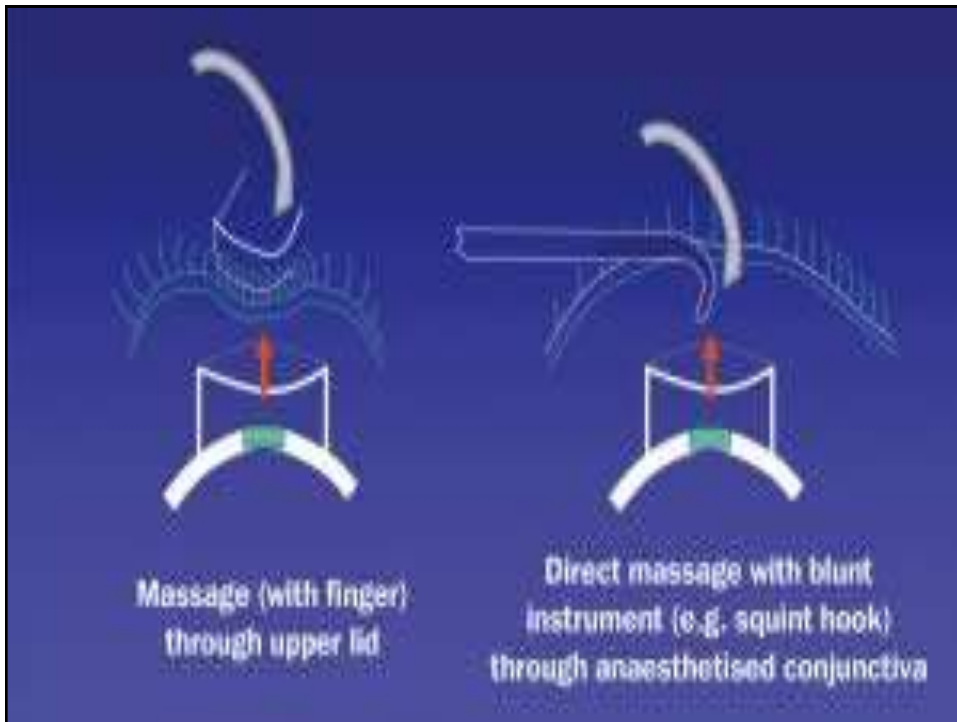
- All that stands between a good result and a flat anterior chamber are your flap sutures.
- **Active** interventions occurring in about half of post-operative patients at some stage.
- The rate of scarring depends on ethnicity, use of antimetabolites and the external ocular environment (past medical therapy and previous trachoma, blepharitis, and conjunctival inflammation).

- The best way to prevent or control scarring is frequent – **a minimum of weekly** – reviews.
- Mechanically re-establishing flow is the first priority. This can be achieved by massage, removing releasable sutures, dividing fixed sutures (by laser or needling) and needling of the bleb as a very last resort.

Massage

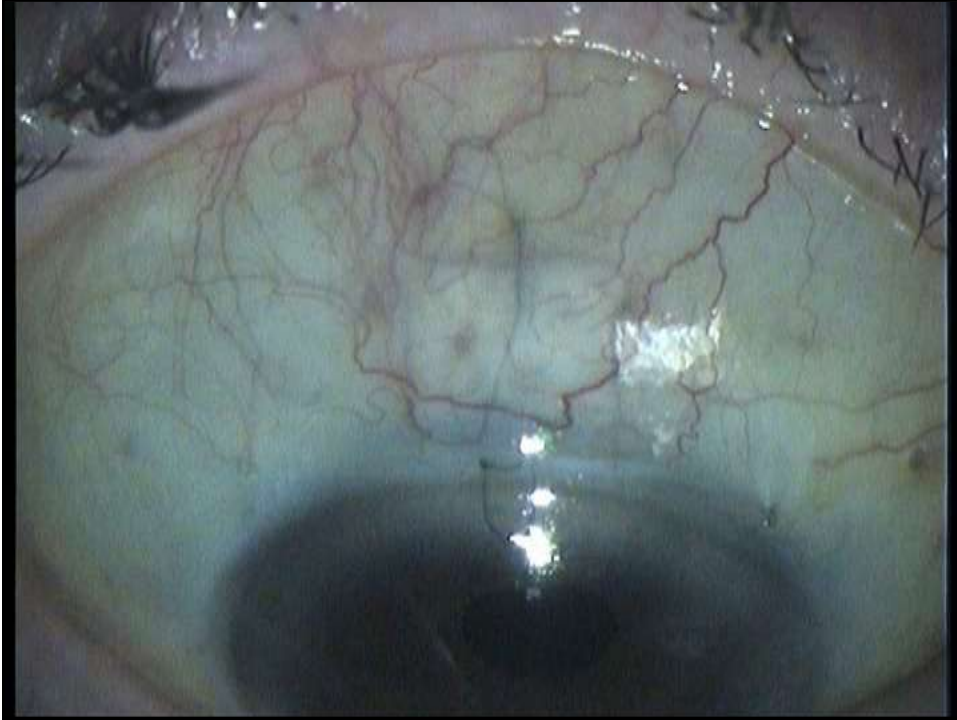
- A trabeculectomy is a guarded fistula. Pushing on the guard will not achieve drainage! You need to 'fishmouth' the posterior opening by applying pressure to the sclera, just behind the posterior end of the scleral flap.
- This means the patient needs to be looking down as far as possible so you are able to apply the pressure in the correct place.





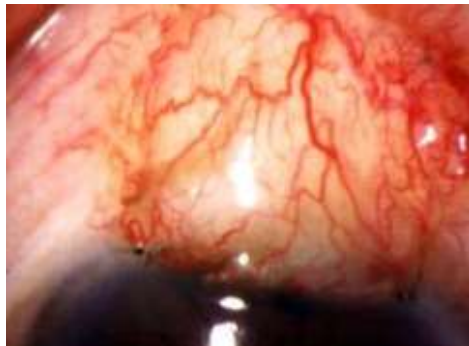
Removal of flap sutures

- Removing releasable sutures is the simplest and quickest approach by far, so give serious consideration to routine use of these sutures in your surgery (betadine 5%).
- Lasering/ breaking a fixed suture using suturelysis lens. (blue menthal)



Conj Sutures

- **Must** be removed by third week, unless it cannot be seen and very difficult to remove.

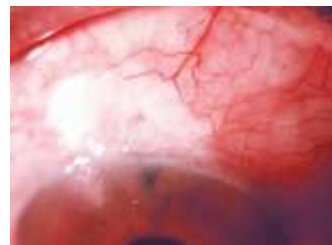
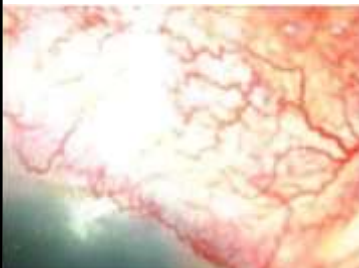
POST OP MEDS

- Steroids 2hourly 2-3 months.
- Steroids ointment.
- Sub tenon steroids: should always be considered in patients who are unable or unreliable in taking their drops regularly.
- Antibiotics Qds for 1 month.

Post – op course

- Early signs of scarring must be noticed and actively dealt with.
- Clinicians are not usually aggressive enough in dealing with early scarring.



Sub conj injection

What?

- 5FU 0.2ml+ Dexamethasone 0.2 ml+ Lignocaine 0.1 ml
- 0.1mg/ml MMC

When?

with removal of last releasable suture

How?

Adequate anaesthetic is essential. Get the patient to look down and administer the anaesthetic drops to the upper bulbar conjunctiva.

Sub conj injection

- Enter the conjunctiva to the temporal side and behind the scleral flap. **Never** inject into a bleb cyst because the forces dictate that the injection will enter the anterior chamber using the line of least resistance. (Should the 5FU enter the anterior chamber, go straight to theatre and wash the chamber out).
- Inject slowly; the stretch receptors produce the most discomfort, so you want to try to avoid this; and, in addition, it gives the 5FU a chance to dissipate.

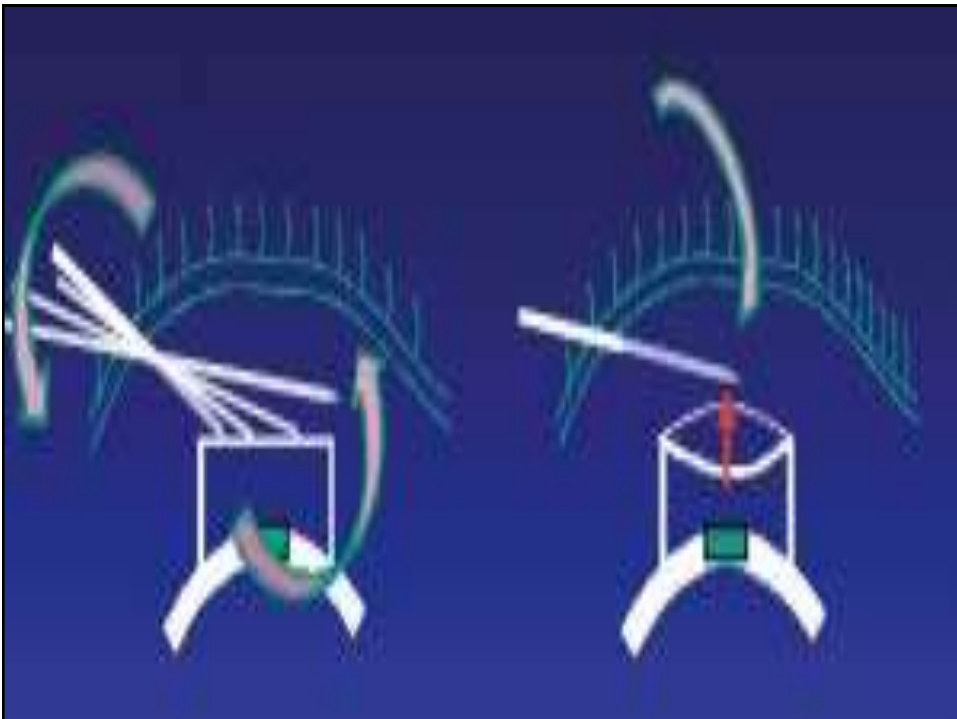
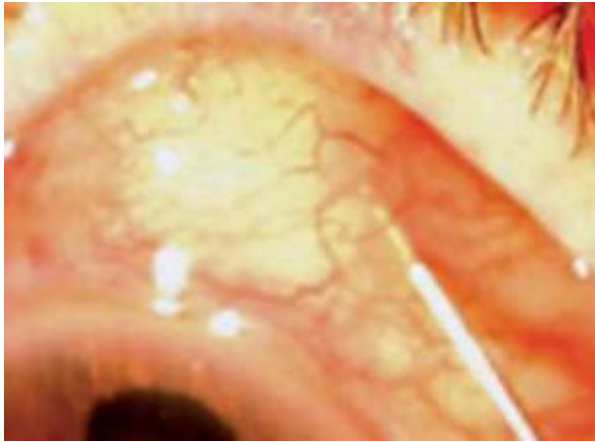
Sub conj injection

- Once you have completed the injection do not withdraw the needle immediately but rather hold for another minute or so if possible. This gives the rest of the fluid a chance to dissipate, and prevents it leaking directly back out of your needle track onto the surface of the eye.
- 5FU toxicity largely comes from 5FU leaked onto the surface of the eye so it is vital to prevent this. After withdrawal of the needle, wash the eye with saline to remove any leaked 5FU.

Needling

- When examining the bleb, the most frequent site of failure is either scarring at the edge of the scleral flap with flat overlying tissues, or else encapsulation of the bleb with a raised profile.
- Gonioscopy to ensure the sclerostomy is patent and free from internal obstruction.
- When? The start of failure not after it has been failed for long time

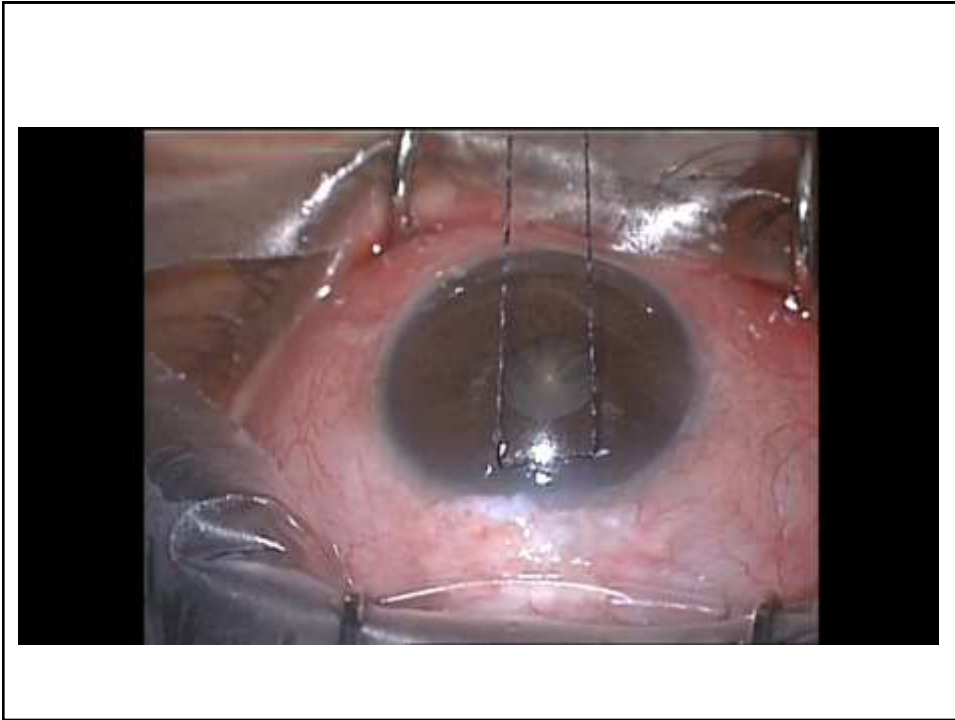
Needling





Needling

- Use of adequate anaesthesia (use topical anaesthetic followed by sub-conjunctival lignocaine 2%), a speculum, vascular constriction (use phenylephrine because it is handy in the clinic), and povidone iodine (or a similar preparation) make a world of difference.

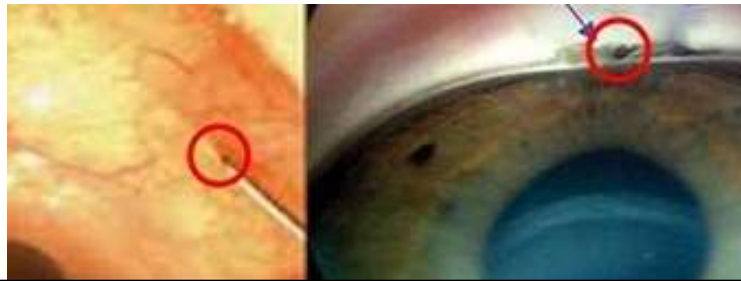


Needling

- Most practitioners enter the conjunctiva (25-30 G)at a distance from the area of scarring to be perforated and use a 'slicing' action to open a good-sized drainage channel. Plan your approach carefully and only work on the area of obstruction to flow nasally or temporally.

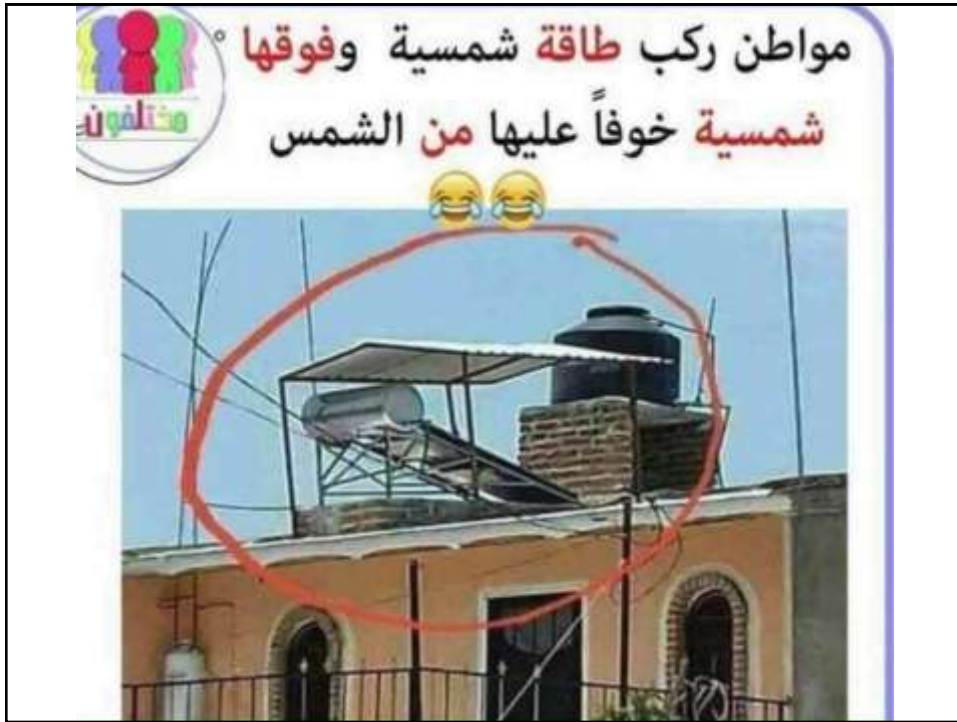Needling

- The most common complication when needling is haemorrhage – either sub-conjunctivally or into the anterior chamber. If your view is obscured, then you should stop and try another time.

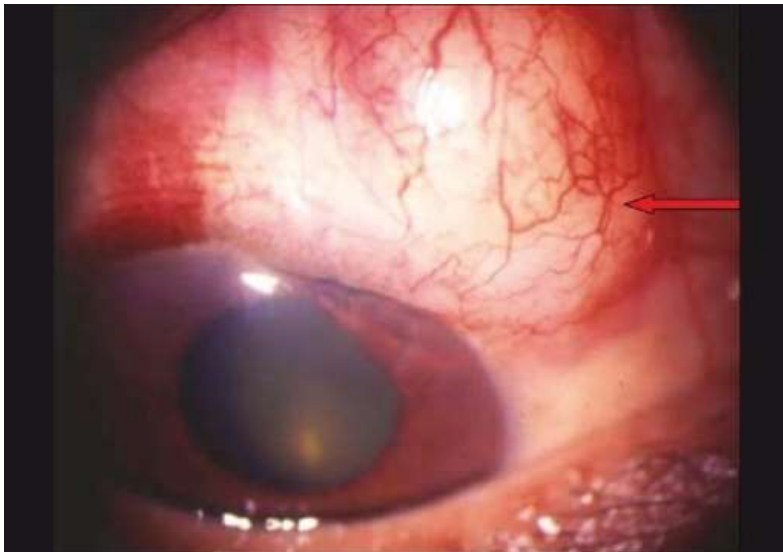

Needling

- The other post-needling complication is hypotony. If the anterior chamber has significantly shallowed, let the patient rest and see if it reforms spontaneously. If it does not, then introducing viscoelastic to the anterior chamber is your best option, with regular review as appropriate.



Tenon cyst



Revision of Traby

- Valving, iris incarceration, early failure.
- if within four weeks of surgery, then under general anaesthesia if at all possible. The eye is already inflamed from the first operation (and the complications). This can make the field more tricky; local anaesthetic does not work so well since it is rapidly washed away even with the use of adrenaline. In addition, the patient is all the more anxious due to the need for repeat surgery (as are you).

Revision of Traby

- General anaesthesia offers a much better environment for both patient and surgeon. In addition, the operation is much faster; a 'quick extra suture' can be less than quick under local anaesthesia.
- **AC maintainer.**

Thank You

ahmedelkarmouty@hotmail.com