

Choosing the Procedure

- ▣ ↑ success rate
- ▣ Target the pathology
- ▣ Not jeopardize success of other procedures

Viscotrabeculotomy in Congenital Glaucoma


Hala Elhilali, MD

Rehab Kassem, MD

Mohamed Amr Salah Eldin, MD

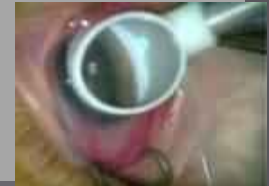Ola Zakaria, MSc

Goniotomy



Goniotomy

- Advantages:
 - Under direct visualization
 - Attacks defective tissue directly
 - Does not disturb conjunctiva
- Disadvantages:
 - Requires clear cornea

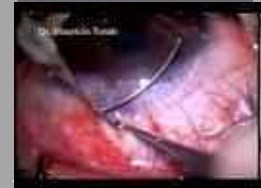

Viscotrabeculotomy

- ▣ Advantages:
 - Prevents postoperative hge
 - Reduces fibroblastic proliferation
 - Decreases adhesions to incision lips

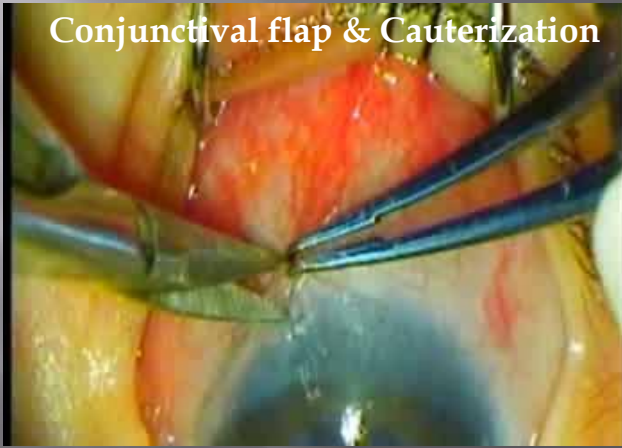
Trabeculotomy

- ▣ Advantages:
 - Cloudy cornea.
- ▣ Disadvantages:
 - Difficulty in finding Schlemm's canal.
 - False passage possible.
 - 50% require > 1 procedure.



Viscotrabeculectomy

Conjunctival flap & Cauterization

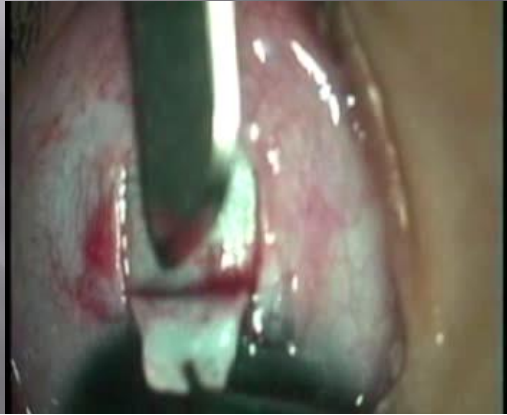

Viscotrabeculectomy

- Disadvantages:
 - IOP elevation
 - Delay absorption of hyphema

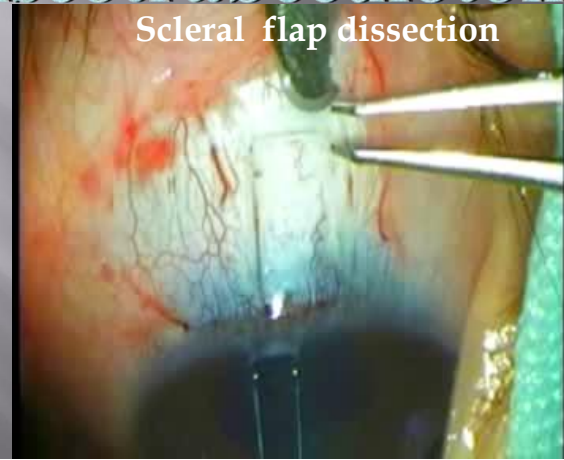
Viscotrabeculotomy

Dissection to proper depth



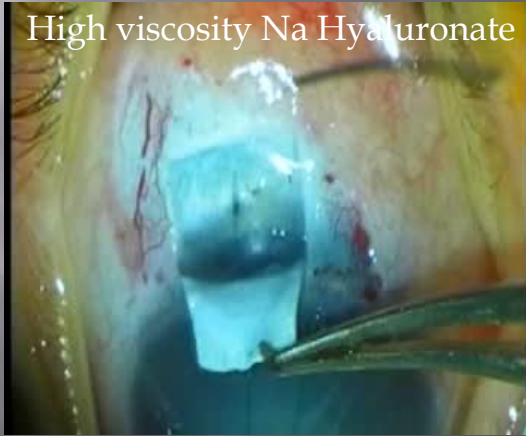Viscotrabeculotomy

Scleral flap dissection



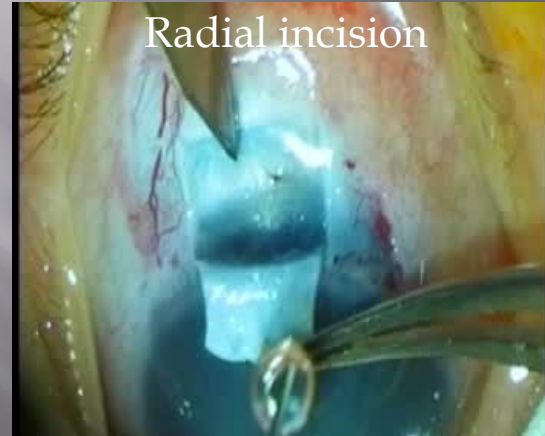Viscotrabeculotomy

High viscosity Na Hyaluronate



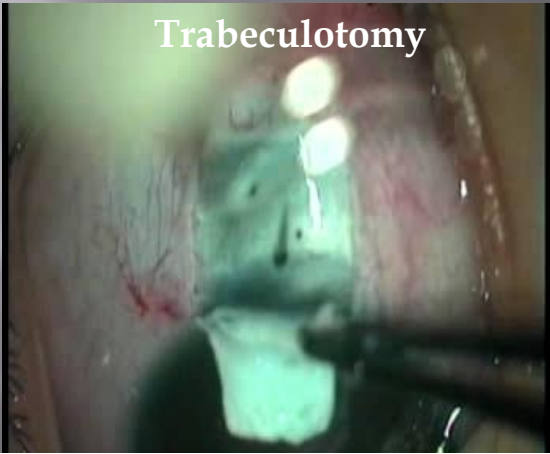Viscotrabeculotomy

Radial incision



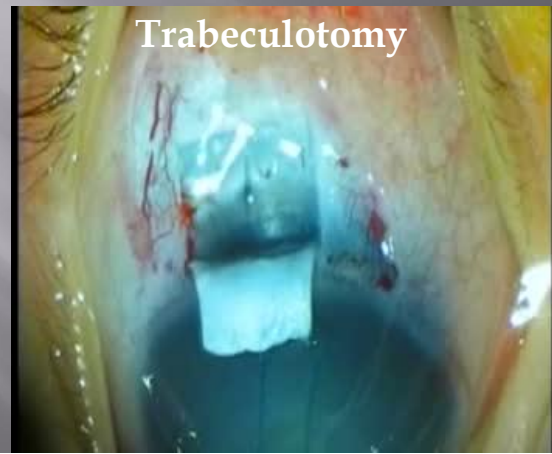Viscotrabeculotomy

Trabeculotomy

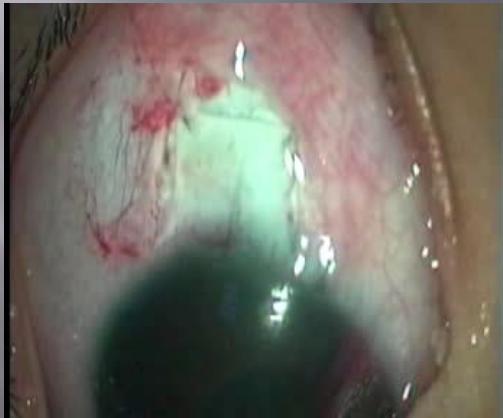

Viscotrabeculotomy

Trabeculotomy



Viscotrabeculotomy



Viscotrabeculotomy

Reinjection

