

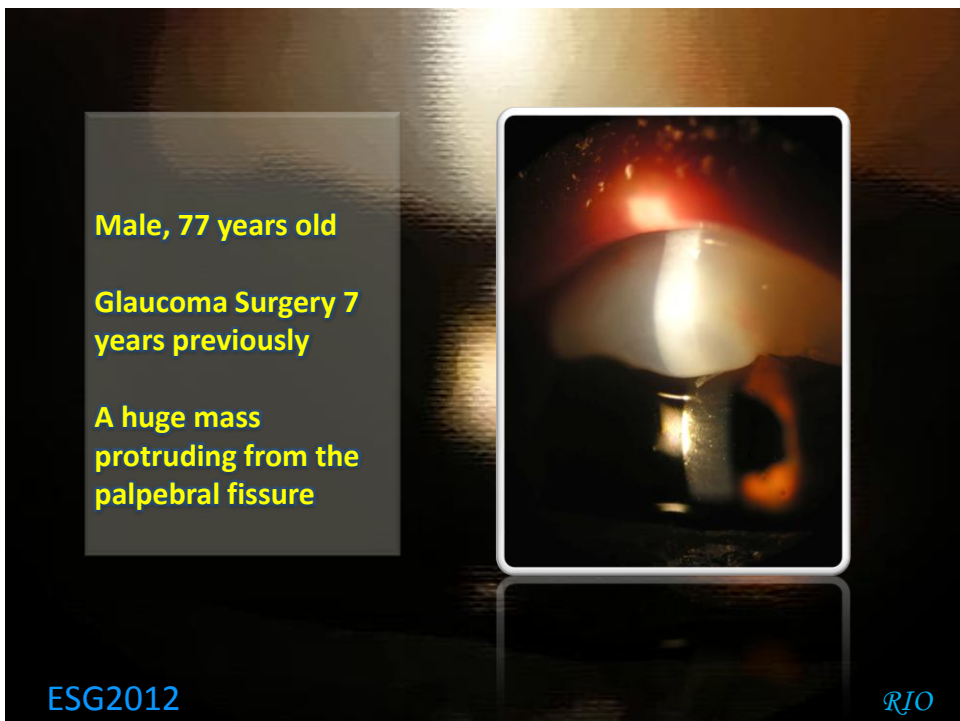


The Overhanging Bleb

And Hypotony Syndrome

Ahmad K Khalil, MD, PhD, Cairo, Egypt


ESG2012 RJO



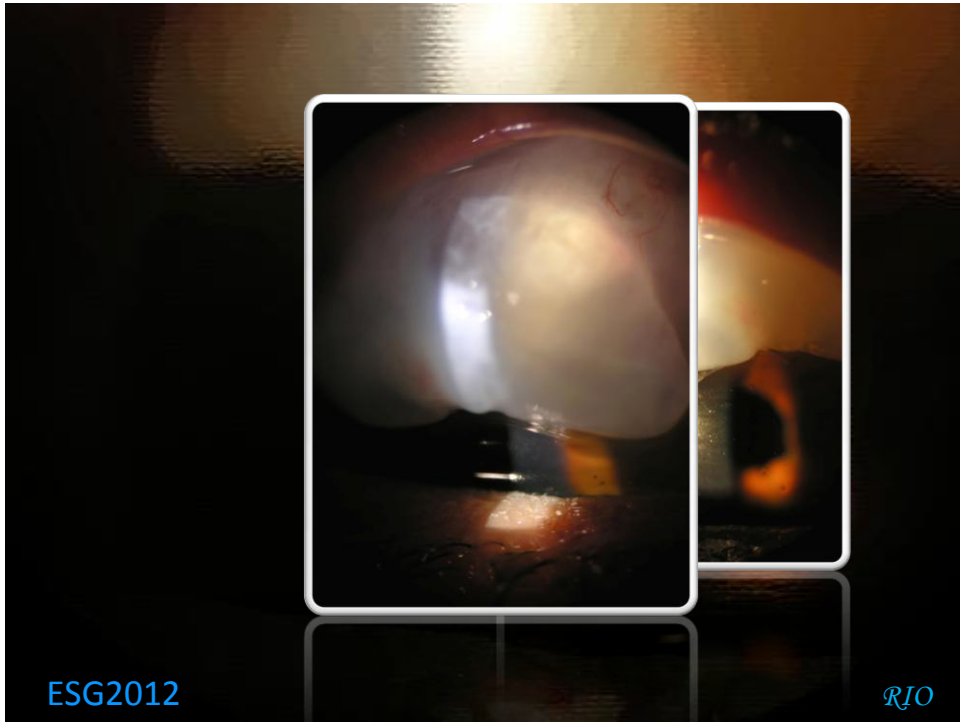
Male, 77 years old

Glaucoma Surgery 7 years previously

A huge mass protruding from the palpebral fissure



ESG2012 RJO

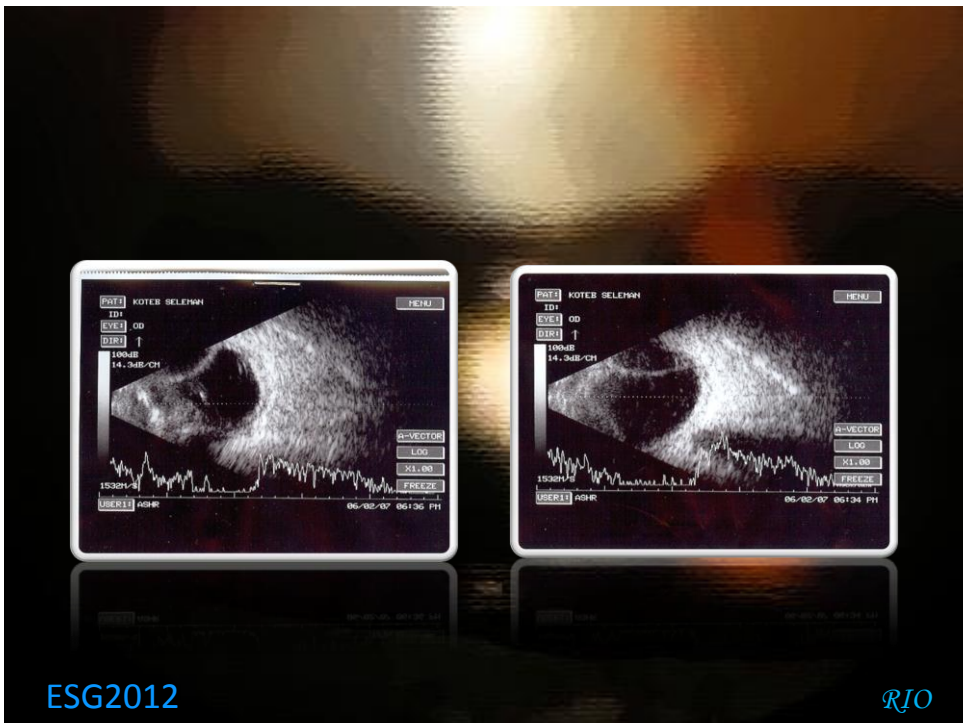
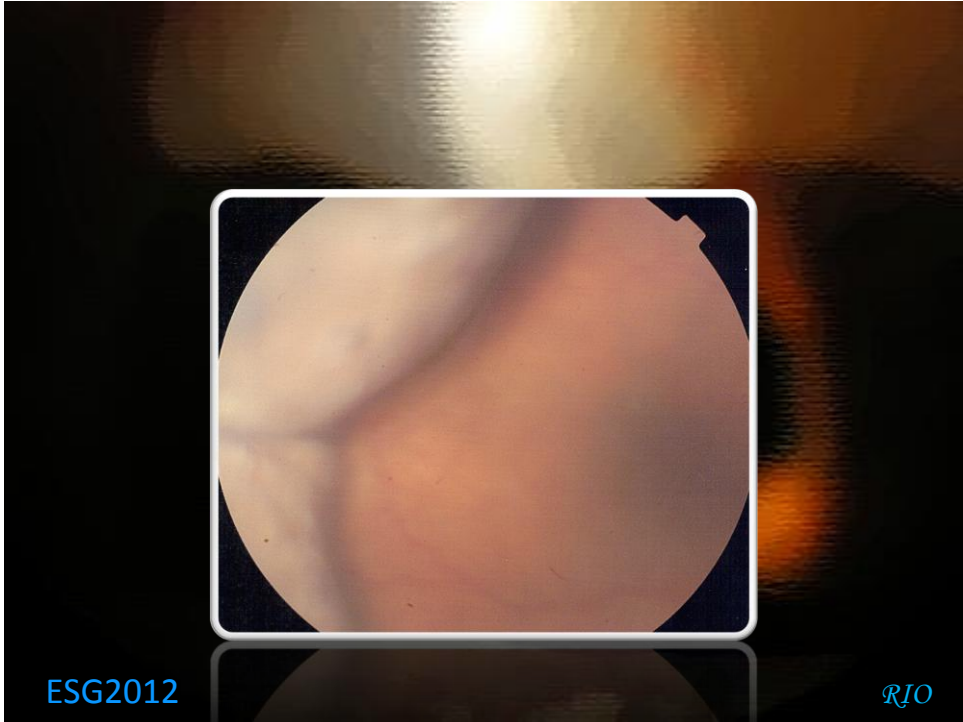

An Overhanging Bleb with Hypotony

- BCVA: 0.5
- IOP: 2-3mmHg

ESG2012 *RJO*

This complex block features a title and a list of clinical findings on the left, and an intraoperative photograph on the right. The title "An Overhanging Bleb with Hypotony" is written in yellow text on a dark background. The list includes "BCVA: 0.5" and "IOP: 2-3mmHg". The photograph on the right is identical to the one in the top image, showing a large, white, overhanging bleb on the sclera. The background is dark, and the lighting is focused on the surgical site.



Management Options

- Medical
- Drainage of chronic suprachoroidal fluid
- Excision of bleb
- Fistula?

ESG2012

RJO

ESG2012

RJO

1 week postop

- IOP still soft
- Choroidal detachment

ESG2012

RJO

2 weeks

- BCVA: 0.4
- IOP: 18
- Choroidal Detachment?!, clinically barely detectable, with some overlying retinal mottling

ESG2012

RJO

1 month

- BCVA: 0.4
- IOP: 12
- Visible bleb

ESG2012

RJO

3 years Postop

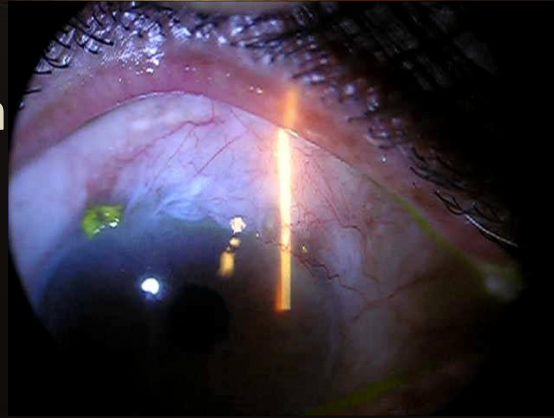
- BCVA: 0.8
- IOP: 12mmHg

ESG2012

RJO

3 Years Postop

- BCVA: 0.8
- IOP: 12mm



ESG2012

RJO



ESG2012

RJO