

PSUDOPHAKIC GLAUCOMA IN A UVEITIC EYE

Mostafa Nabih
Cairo university

- ▣ 18 year old male
 - ▣ History of uveitis of unknown cause
(After extensive investigations.)
- Left eye lost from pseudophakic glaucoma
after cataract surgery
- Right eye history of cataract surgery (months)
Inflammation and glaucoma
Failed medical control of glaucoma

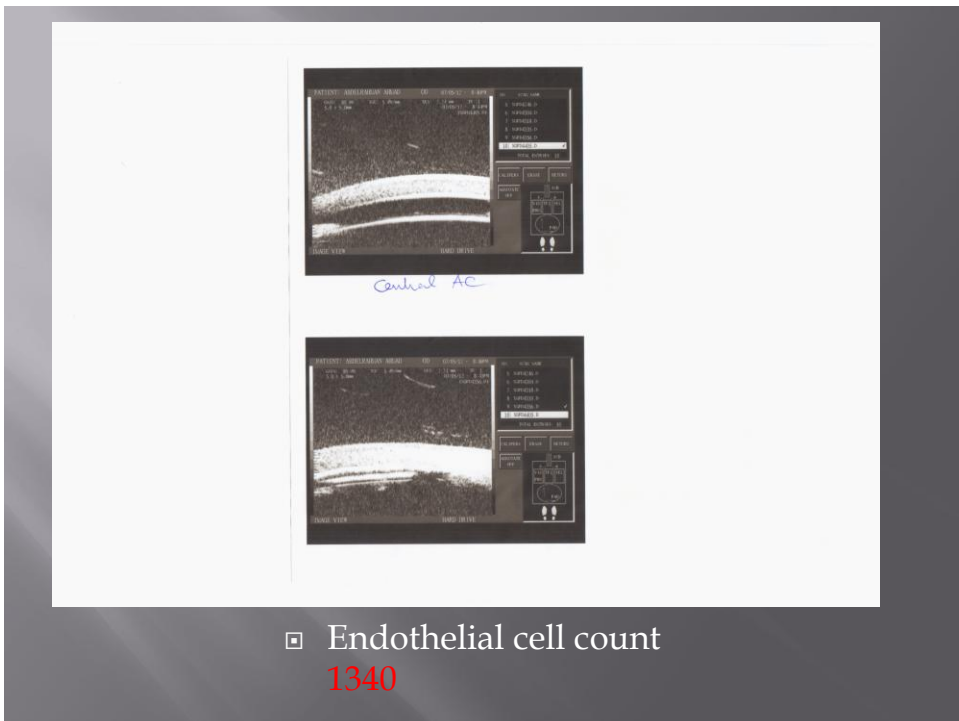
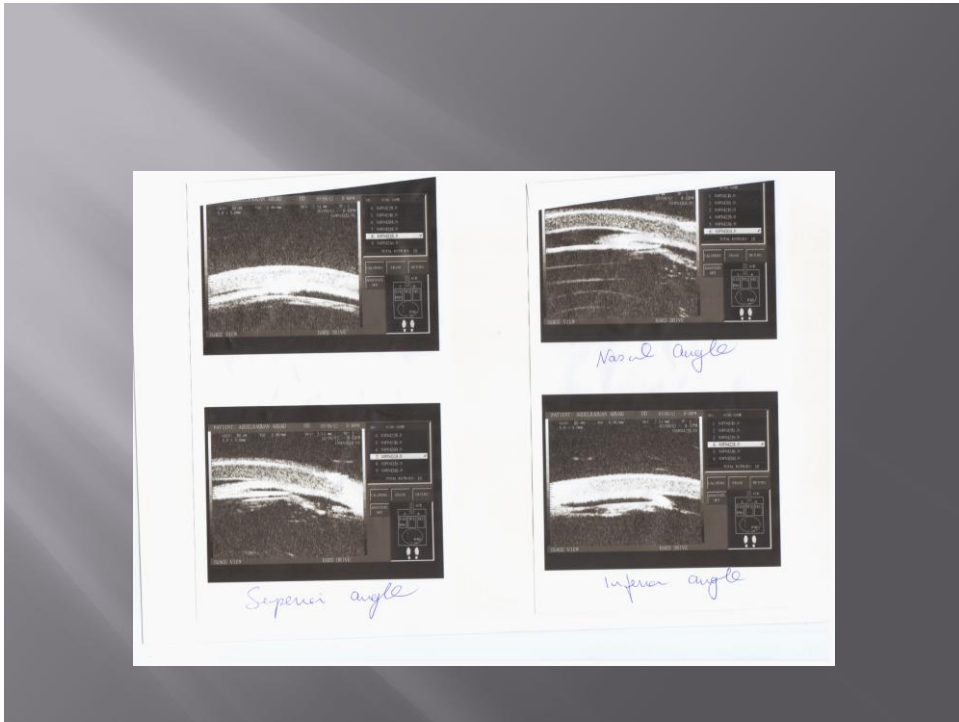
What to do


Cyclodiode laser

- ▣ In Germany

- ▣ Low tension for 2 months
- ▣ Progressive synicheae
- ▣ High IOP
- ▣ Complete angle closure
- ▣ AC practically lost

Vision 0.63





- ▣ Fully formed aphakic depth AC
- ▣ Normal intraocular pressure
- ▣ No increase of corneal thickness
- ▣ Visual acuity 0.63

6 weeks later

As if we did nothing

- ▣ Progressive synicheae
- ▣ High IOP
- ▣ Complete angle closure
- ▣ AC practically lost

Vision 0.63