


# PUPIL RECONSTRUCTION

**TAREK EID, MD**  
PROFESSOR OF OPHTHALMOLOGY  
TANTA UNIVERSITY

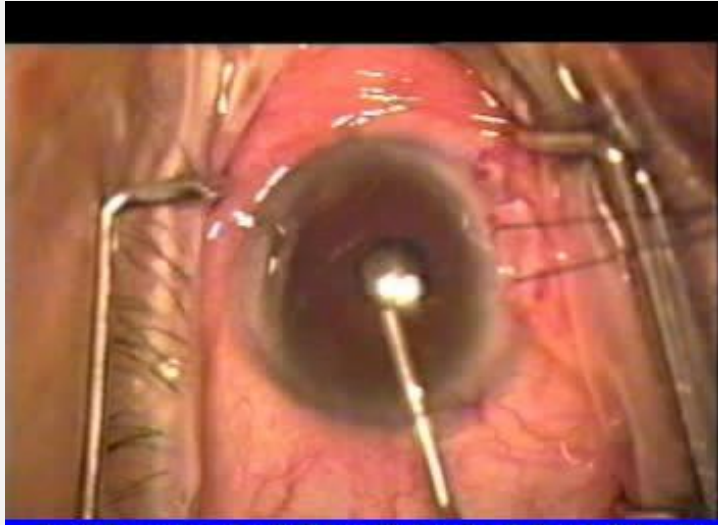
## PUPIL RECONSTRUCTION

### MEASURES TO DILATE A NARROW PUPIL

- Dilating drops
- Viscoelastic injection
- Lysis of posterior synechiae
- Peeling of fibrotic membrane
- Mechanical pupil expansion
- Iris retraction hooks
- Maluigyn ring or pupil expander
- Multiple sphincterotomies
- Sector iridotomy

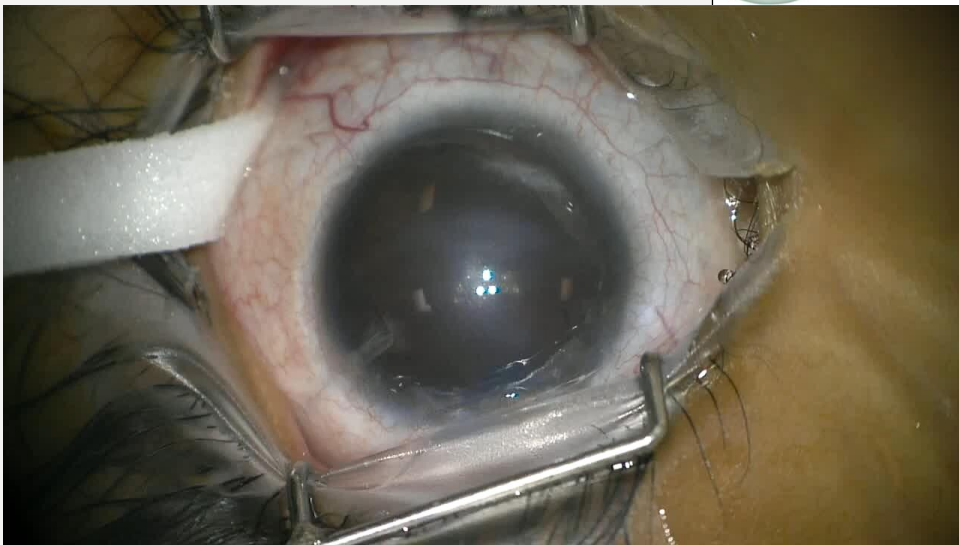


## **MECHANICAL PUPIL EXPANSION FOR STIFF, NONDILATING PUPIL BEFORE CATARACT SURGERY**

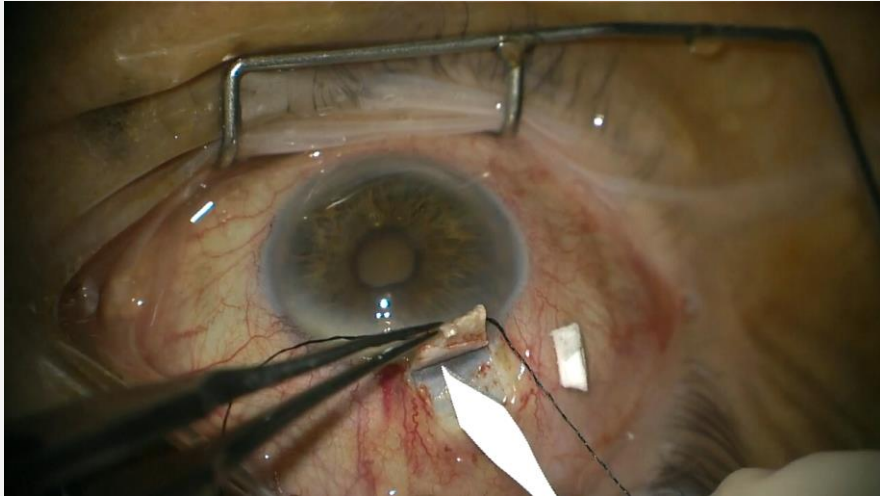


Pupil Expanders for Stiff Nondilating Pupil, Tarek Eld, MD

## **IRIS RETRACTION HOOKS**



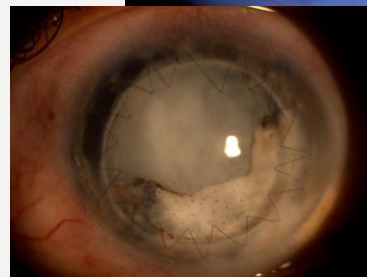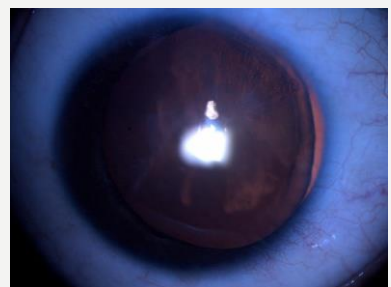
## **MALUIGYN RING FOR PSEUDOEXFLIATION WITH STIFF PUPIL (SAME -SITE PHACO-TRAB OP)**



## **PUPIL RECONSTRUCTION**

### **MEASURES TO RECONSTRUCT A DILATED OR DISTORTED PUPIL**

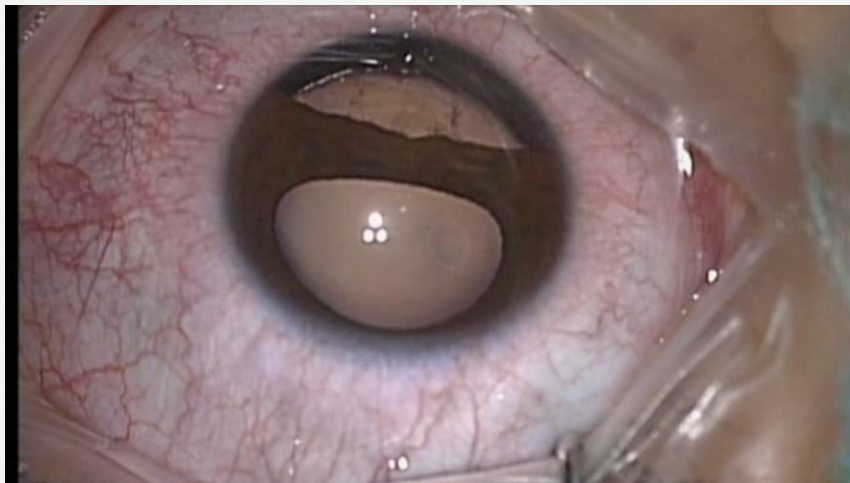
- Iris suturing
- Pupil cerclage
- Aniridia intraocular lens
- Aniridia tension rings
- Artificial iris implant




## **PUPIL RECONSTRUCTION AFTER PENETRATING TRAUMA WITH NEAR HEMIANIRIDIA**

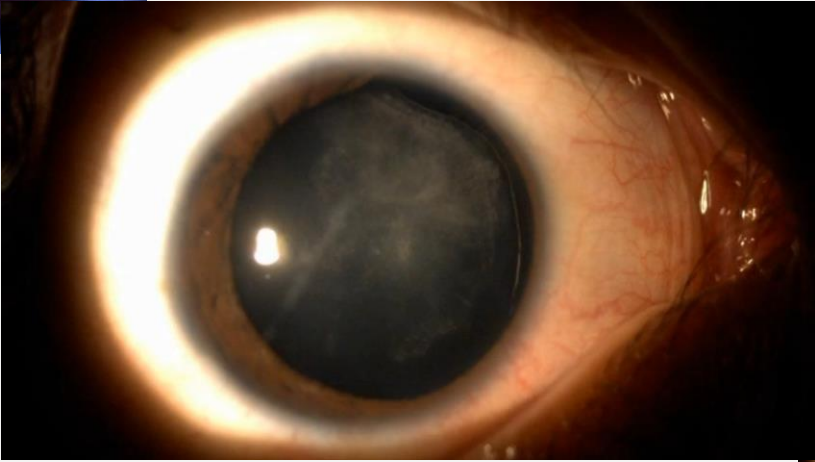


## **REPAIR OF TRAUMATIC IRIDODIALYSIS WITH DECENTERED PUPIL**

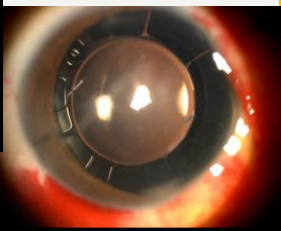




**TRAUMATIC IRIS DEFICIENCY WITH CATARACT**

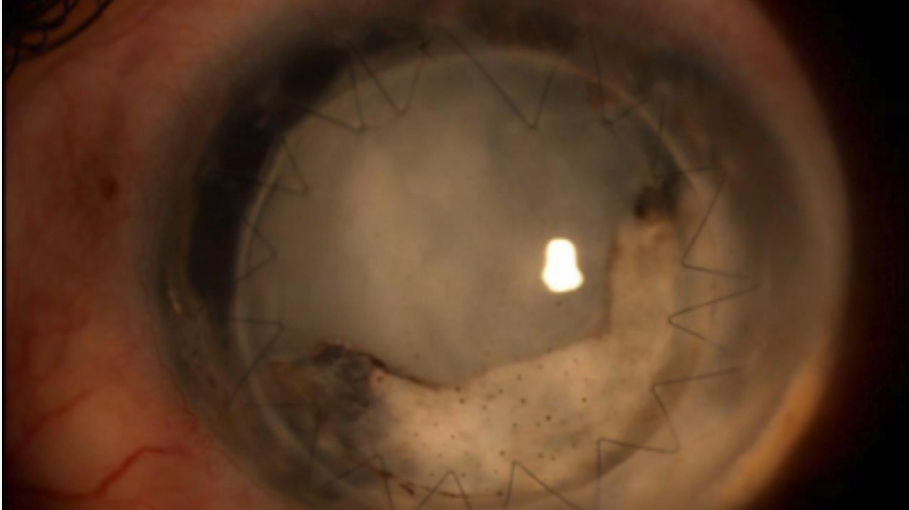


**AFTER PHACO AND INSERTION OF ANIRIDIA TENSION RINGS**


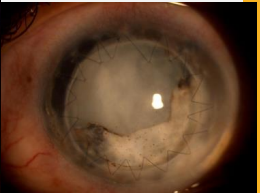


This slide illustrates the clinical presentation and surgical management of traumatic iris deficiency with cataract. The top-left image shows a patient's eye with a dark, irregularly shaped pupil and a dense, white cataract. The central image is a large, detailed view of the eye after phacolytic cataract extraction (phaco) and the insertion of aniridia tension rings, showing a well-defined, circular pupil. The bottom-right image shows the eye with the tension rings in place, demonstrating the restored pupillary structure.

**TRAUMATIC CORNEAL SCAR, IRIS DEFICIENCY WITH CATARACT & GLAUCOMA**

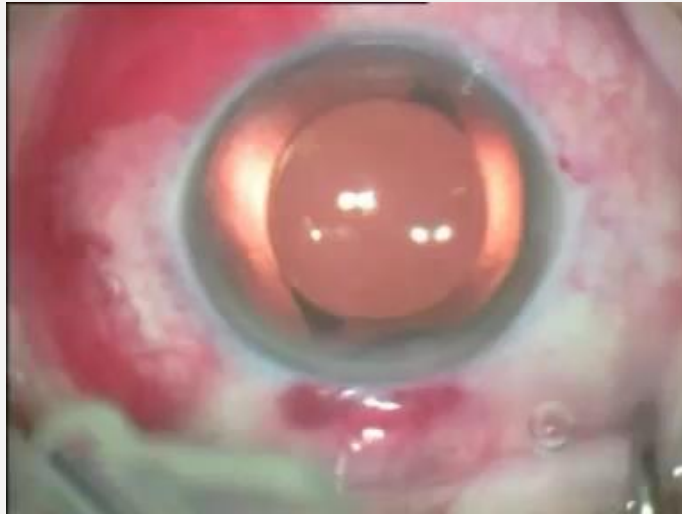

**AFTER PKP, THEN PHACO -VISCOTRAB AND INSERTION OF ANIRIDIA LENS**



This slide illustrates the clinical presentation and surgical management of traumatic corneal scar, iris deficiency with cataract and glaucoma. The central image is a large, detailed view of the eye after penetrating keratoplasty (PKP), phacolytic cataract extraction (phaco) with viscotrabeculectomy, and the insertion of an aniridia lens, showing a well-defined, circular pupil. The top-right and bottom-right images show the eye with the aniridia lens in place, demonstrating the restored pupillary structure.

# **ARTIFICIAL IRIS IMPLANT**



**THANK YOU  
FOR YOUR  
ATTENTION**

**TAREK EID**